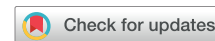

# Evidence for and against vertical transmission for severe acute respiratory syndrome coronavirus 2



Audrey Lamouroux, MD, PhD; Tania Attie-Bitach, MD, PhD; Jelena Martinovic, MD, PhD; Marianne Leruez-Ville, MD, PhD; Yves Ville, MD

Coronavirus disease 2019 (COVID-19) leads to severe conditions such as severe pneumonia and several affected pregnant women are in a critical condition.<sup>1</sup> Vertical transmission of many microorganisms from an infected mother to her fetus can lead to devastating results. Vertical transmission can be antenatal or per-partum, although perinatal or postnatal transmission can also have severe consequences. During the antenatal period, transmission of infection has different effects across the 3 trimesters of pregnancy. In addition, transplacental passage of pathogens is influenced by advancing gestational age; as a result, the severity of fetal injuries decreases from embryopathy in the first trimester, fetal infection in the second trimester, to immune response–driven damage and symptoms in the second and third trimester.

Based on the results of real-time polymerase chain reaction (RT-PCR) assays for the identification of severe acute respiratory syndrome coronavirus 2 (SARS-CoV-2), primary reports from China suggested that intrauterine vertical transmission was unlikely.<sup>1</sup> However, the introduction of serologic testing of cord and neonatal blood for SARS-CoV-2 has raised concerns.<sup>2</sup>

Viruses of the *Coronaviridae* family possess a single strand, positive-sense RNA genome. The following 3 types of human coronavirus cause acute and severe maternal illnesses: Middle East respiratory syndrome coronavirus (MERS-CoV) causes Middle East respiratory syndrome (MERS); SARS-CoV causes

severe acute respiratory syndrome (SARS); and SARS-CoV-2 causes COVID-19.<sup>1</sup> SARS-CoV-2 strains show 50% and 79% sequence homology to SARS-CoV and MERS-CoV, respectively.<sup>1</sup> A major issue of any published study to date is the relative inaccuracy of available diagnostic test results. Indeed, the sensitivity of RT-PCR testing is around 63%, 93%, and 29% in nasal swabs, bronchoalveolar lavages, and feces of patients with SARS-CoV-2 infection, respectively.<sup>3</sup> Therefore, testing specimens from multiple sites may improve the detection rate and reduce false-negative diagnoses. Here, the presence of total (Ab) and immunoglobulin G (IgG) antibodies seemed to appear within 2 weeks from symptoms onset in patients with SARS-CoV-2 infection; and the introduction of SARS-CoV-2 serology is a rapidly evolving field of research and much-needed aid in the management of the pandemic. Notably, the fetus acquires the ability to produce serum immunoglobulins early in gestation. Because maternal IgG transfer freely and increasingly in gestation, the fetus shows a repertoire of maternal IgG antibodies. However, maternal immunoglobulin M (IgM) antibodies do not cross the placenta. In addition, the presence of maternal IgM antibodies in fetal or cord blood indicates fetal immune response. Anti-SARS-CoV-2 IgM antibody assays used in perinatal studies in China claimed a sensitivity and specificity of 70.2% to 88.2% and 96.2% to 99%, respectively, as assessed in 1 study and by the manufacturer; however, both evaluation results were published in Chinese.<sup>2</sup> Thus, performance characteristics of the SARS-CoV-2 IgM require further study.

SARS-CoV-2 is thought to be transmitted through respiratory droplets.<sup>1</sup> The viremia is found in 1% of patients with symptoms of COVID-19<sup>3</sup> and is generally low and transient, suggesting that the virus is unlikely to be transmitted across the placenta. Few placental samples have been studied to date,<sup>4</sup> and the results of RT-PCR testing showed no presence of the virus (Supplemental Table 1). Fetal pathologists should nevertheless continue to ensure that standard precautions are followed when handling biologic samples from patients suspected with SARS-CoV-2 infection. Histologic examination of 3 placentas did not provide any evidence of placental infection or inflammation, namely, no villitis or chorioamnionitis. In all 3 placentas, vascular villous lesions such as fibrin deposition within and around the villi and infarcts were reported to be likely related to maternal comorbidities, including preeclampsia.<sup>4</sup> Like SARS-CoV, SARS-CoV-2 also uses angiotensin-converting enzyme 2 (ACE2) as a cell receptor.<sup>1</sup> RNA expression profile of ACE2 in the trophoblast

From the Department of Fetal Pathology and Genetics, Nimes and Montpellier University Hospitals, University of Montpellier, Montpellier, France (Dr Lamouroux); Department of Embryology, Fetal Pathology, and Genetics, Imagine Institute, Necker-Enfants Malades Hospital, University of Paris, Paris, France (Dr Attie-Bitach); Department of Fetal Pathology, Antoine-Béclère Hospital, Paris Saclay University, Clamart, France (Dr Martinovic); Departments of Medical Virology (Dr Leruez-Ville) and Obstetrics and Fetal Medicine (Dr Ville), Necker-Enfants Malades Hospital, University of Paris, Paris, France.

All authors declare that they contributed significantly to the review of the literature and the writing of this manuscript. They certify that this manuscript or the data of this study have not been submitted elsewhere.

No funding was deemed necessary for this study.

The authors report no conflict of interest.

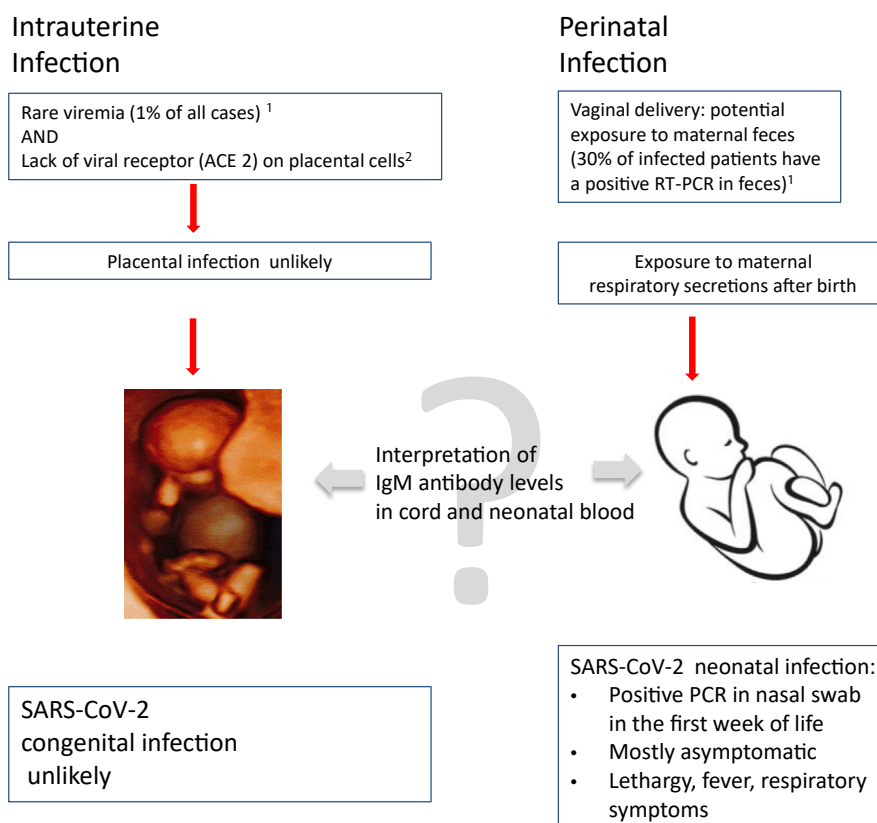
Corresponding author: Yves Ville, MD. [ville.yves@gmail.com](mailto:ville.yves@gmail.com)

0002-9378/\$36.00 • © 2020 Elsevier Inc. All rights reserved.  
<https://doi.org/10.1016/j.ajog.2020.04.039>

 Click Supplemental Materials under article title in Contents at [ajog.org](https://ajog.org)

## FIGURE

## The possibility of vertical and perinatal infection



Lamouroux. Evidence for and against vertical transmission for severe acute respiratory syndrome coronavirus 2 (coronavirus disease 2019). *Am J Obstet Gynecol* 2020.

appears very low between 6 weeks' gestation and 14 weeks' gestation, as assessed by combined single-cell transcriptome profiles from the early maternal-fetal interface.<sup>5</sup> Therefore, mother-to-fetus transmission of SARS-CoV-2 during the first trimester seems unlikely. It is, however, possible that severe maternal respiratory failure and hypoxemia may disrupt uterine placental flow and cause miscarriage.

The dynamic of the COVID-19 pandemic has not allowed for any meaningful cohort after maternal infection in the second trimester of pregnancy to be reported with perinatal outcomes; furthermore, in this study, the large values relate to cases of infection and delivery in the third trimester of pregnancy.

A total of 71 women were reported to have undergone cesarean delivery, with 64 of 71 (90.1%) women delivering 1 to 25 days after symptoms onset (Supplemental Table 2). Using RT-PCR, intrauterine vertical transmission (Supplemental Table 1) of infection was assessed in 10 amniotic fluid samples and in 5 placental samples; all results returned negative. Of note, results of maternal serum and vaginal swabs from 3 patients with symptoms of COVID-19 and breast milk from 10 patients with symptoms of COVID-19 that were tested for SARS-CoV-2 all returned negative. Furthermore, in 12 cases, results from RT-PCR of cord blood that was tested for SARS-

CoV-2 all returned negative (Supplemental Table 1). One newborn delivered by cesarean delivery who had no contact with her mother had a positive RT-PCR result in a pharyngeal swab collected 36 hours after birth. However, an iatrogenic transmission could not be excluded (Supplemental Table 1). In a single series of 33 neonates delivered by mothers with symptoms of COVID-19, 3 neonates (9%) with symptoms of COVID-19 tested positive for SARS-CoV-2 in an RT-PCR of anal and nasopharyngeal swabs. Symptoms that were reported at day 2 of life in 2 of the 3 neonates born at 40 weeks' gestation and 40 4/7 (40 weeks and 4 days) weeks' gestation included lethargy, fever, and vomiting with chest X-ray suggestive of pneumonia. The third neonate who required resuscitation was delivered at 31 4/7 (31 weeks and 4 days) weeks' gestation and had bacterial sepsis. The symptoms therefore being compatible with sepsis rather than SARS-CoV-2 infection.<sup>6</sup> However, the former 2 cases with early-onset mild symptoms of COVID-19 and positive PCR at day 2 and day 4 of life bring the strongest argument to date in favor of a vertical transmission. However, both infants were resampled on day 6 of life, and RT-PCR performed on multiple sites was negative. The result is also unexpected in the context of a congenital infection with any pathogen. No outcome data later than day 8 of life was provided in this study.

One child had elevated IgM and IgG antibody levels 2 hours after birth. Nasopharyngeal swabs tested negative on RT-PCR on 5 occasions, and both IgM and IgG antibody levels decreased on day 14 of life and throughout the duration of the assay.<sup>2</sup> Another report described potential serologic evidence of vertical transmission in 2 of 6 infants from mothers with SARS-CoV-2 infection.<sup>2</sup> The overall picture resembles that of passive transfer of maternal antibodies; however, IgM is known to not cross the placenta, and its presence in fetal and/or cord blood could reflect intrauterine infection. However, IgM assays are prone to both false-positive and false-negative results; furthermore, cross reactivity with nonspecific IgM antibodies, presence of rheumatoid factor, or incomplete removal of IgG may be maternal in origin.<sup>2</sup> All reported neonates with infection were born by cesarean delivery 2 to 4 days following symptoms onset; in addition, few newborns delivered vaginally were not suspected of contracting the infection. Although the numbers are small, this supports the possibility of per-partum infection, especially because the virus could not be isolated from vaginal swabs.

More definitive evidence is therefore needed before early findings based on incomplete observations and serologic studies with uncertain results can be used for counseling pregnant women on the risk of congenital infection with SARS-CoV-2 (Figure). However, we should remain aware of another possible pathway toward COVID-19–related perinatal morbidity. Prolonged and severe fetal hypoxia could occur in pregnancies presenting in critically hypoxemic

conditions and requiring intensive and prolonged resuscitation and ventilation. It is too early to have such cases reported in the literature because ischemic-hypoxic lesions could take up to 6 to 8 weeks to develop and be amenable to prenatal or postnatal imaging. Although no recommendations have been issued to date, it is advisable to follow up those cases with fetal and neonatal serial imaging if and when the maternal condition is suitable. ■

---

## REFERENCES

1. Rasmussen SA, Smulian JC, Lednický JA, Wen TS, Jamieson DJ. Coronavirus disease 2019 (COVID-19) and pregnancy: what obstetricians need to know. *Am J Obstet Gynecol* 2020;222:415–26.
2. Kimberlin DW, Stagno S. Can SARS-CoV-2 infection be acquired in utero?: More definitive evidence is needed. *JAMA* 2020 [epub ahead of print].
3. Wang W, Xu Y, Gao R, et al. Detection of SARS-CoV-2 in different types of clinical specimens. *JAMA* 2020. Available at: <https://jamanetwork.com/journals/jama/fullarticle/2762997>. Accessed April 4, 2020.
4. Chen S, Huang B, Luo DJ, et al. Pregnant women with new coronavirus infection: a clinical characteristics and placental pathological analysis of three cases. *Zhonghua Bing Li Xue Za Zhi* 2020;49:E005.
5. Zheng Q, Duan T, Jin L. Single-cell RNA expression profiling of ACE2 and AXL in the human maternal fetal interface. *Reprod Dev Med* 2020 [epub ahead of print].
6. Zeng L, Xia S, Yuan W, et al. Neonatal early-onset infection with SARS-CoV-2 in 33 neonates born to mothers with COVID-19 in Wuhan, China. *JAMA Pediatr* 2020. Available at: <https://jamanetwork.com/journals/jamapediatrics/fullarticle/2763787>. Accessed March 27, 2020.

## ABSTRACT

## Evidence for and against vertical transmission for severe acute respiratory syndrome coronavirus 2

COVID-19 can severely affect pregnant women. Furthermore, issues regarding vertical transmission of severe acute respiratory syndrome coronavirus 2 are emerging. In patients and neonates who are showing symptoms of coronavirus disease 2019, real-time polymerase chain reaction of nasal and throat swabs, sputum, and feces is performed to detect the presence of severe acute respiratory syndrome coronavirus 2. In addition, real-time polymerase chain reaction of vaginal swabs, amniotic fluid, placenta, cord blood, neonatal blood, or breast milk for the detection of severe acute respiratory syndrome coronavirus 2 did not show substantial results. Viremia was present in 1% of adult patients who were showing symptoms of coronavirus disease 2019. Here, we reviewed 12 articles published between Feb. 10, 2020, and April 4, 2020, that reported on 68 deliveries and 71 neonates with maternal infection in the third trimester of pregnancy. To determine whether

infection occurred congenitally or perinatally, perinatal exposure, mode of delivery, and time interval from delivery to the diagnosis of neonatal infection were considered. Neonates with severe acute respiratory syndrome coronavirus 2 infection are usually asymptomatic. In 4 cases, a diagnostic test for severe acute respiratory syndrome coronavirus 2 infection was performed within 48 hours of life. Furthermore, detection rates of real-time polymerase chain reaction and the interpretation of immunoglobulin M and immunoglobulin G antibodies levels in cord and neonatal blood were discussed in relation with the immaturity of the fetal and neonatal immune system.

**Key words:** fetus, immunoglobulin G, immunoglobulin M, placenta, real-time polymerase chain reaction, severe acute respiratory syndrome coronavirus 2